

Total-etch adhesive bonding of a glass ceramic veneer and self-adhesive cementation of a zirconia crown

Clinical Case by Dr. Paulo Monteiro, Portugal

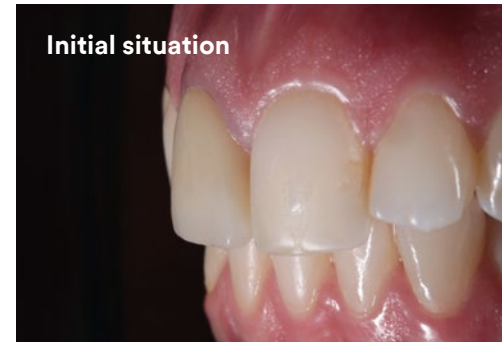

24-year-old patient wanted to enhance esthetics, especially in the upper central incisors. She had an old zirconia crown on tooth 11 with some discoloration and an inadequate cervical margin. Tooth 21 had old composite restorations.

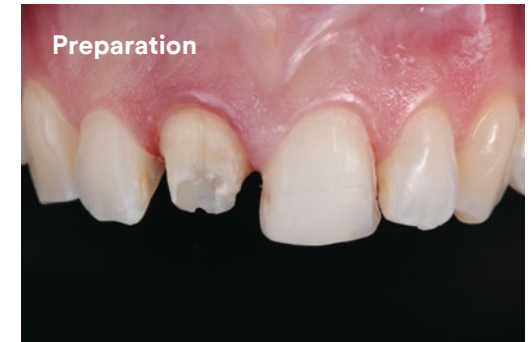In the treatment plan, it was decided to replace the crown on tooth 11 with a new zirconia crown and make a glass ceramic veneer for tooth 21. A direct composite restoration was planned on tooth 22 as well to create a more harmonious smile curve.

3M™ RelyX™ Universal Resin Cement was used for both the self-adhesive cementation of the zirconia crown as well as the esthetic bonding of the glass ceramic veneer. This allowed for a streamlined, more efficient seating process vs. using multiple resin cements.

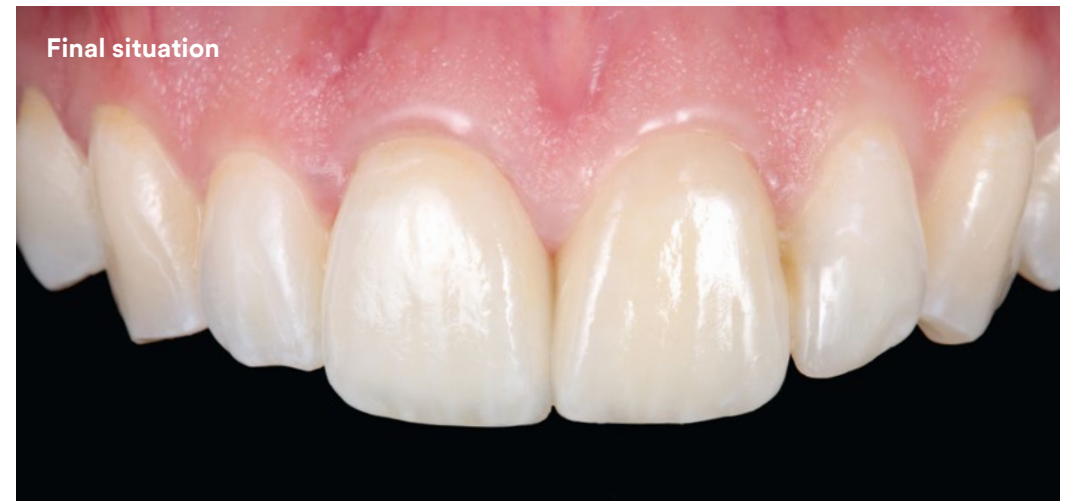The author holds an International Certification in Advanced Aesthetic and Restorative Dentistry and teaches at Instituto Universitário Egas Moniz, Caparica, Portugal.



Initial situation

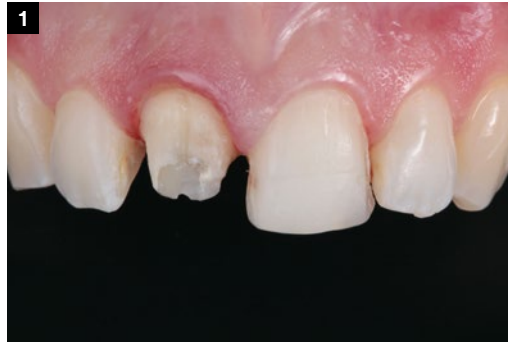

Preparation

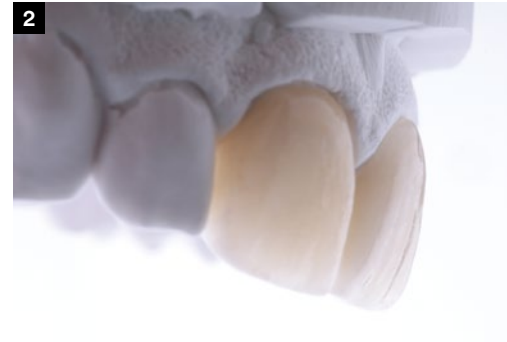

Final situation

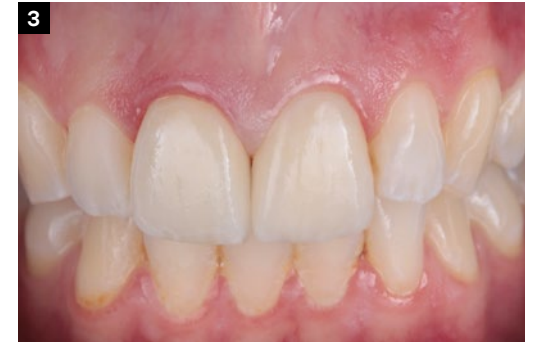**Total-etch
adhesive bonding
of a glass ceramic
veneer and
self-adhesive
cementation of a
zirconia crown**



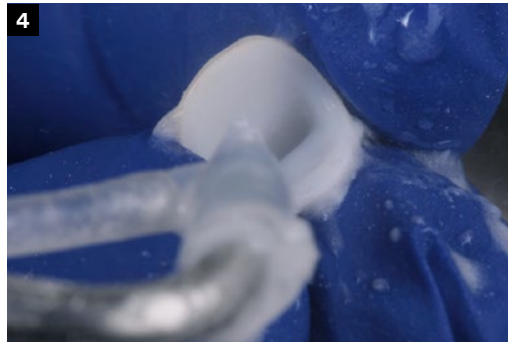
1 Prepared anterior teeth for both a crown and a veneer restoration.



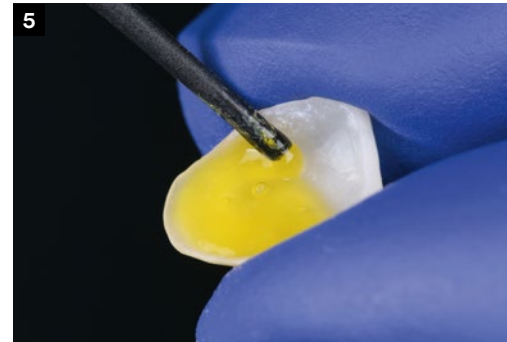
2 Lab made veneered zirconia crown and glass ceramic veneer.



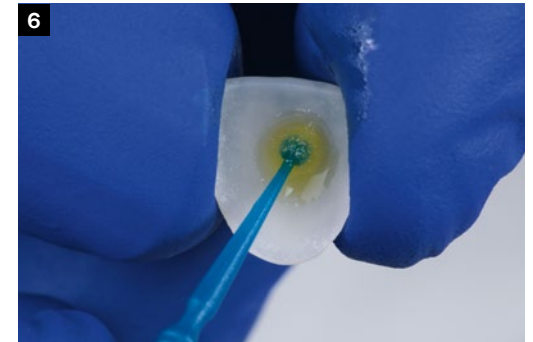
3 Try-In with 3M™ RelyX™ Try-in Paste, shade TR.



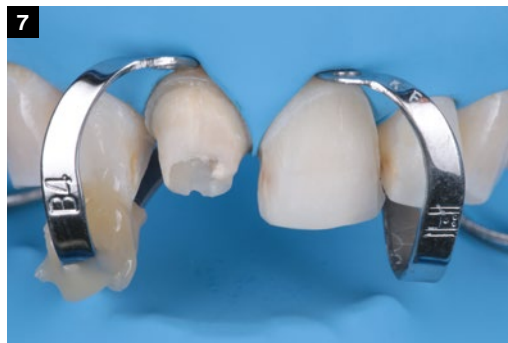4 Sandblasting of the zirconia crown. No primer required.



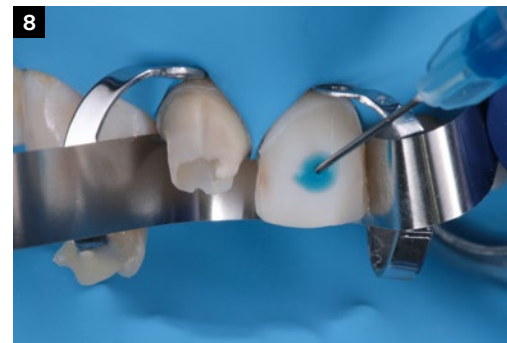5 HF etching of the glass ceramic veneer.



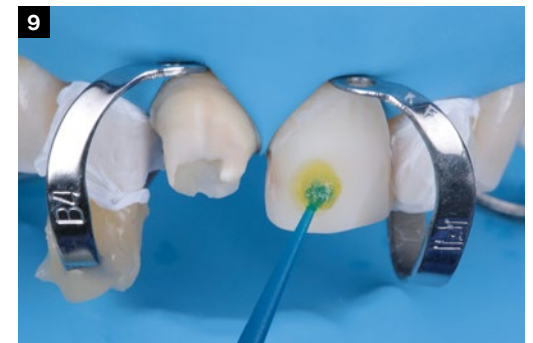6 Application of 3M™ Scotchbond™ Universal Plus Adhesive followed by air drying.



7 Rubber dam in place, preparations ready for pre-treatment.

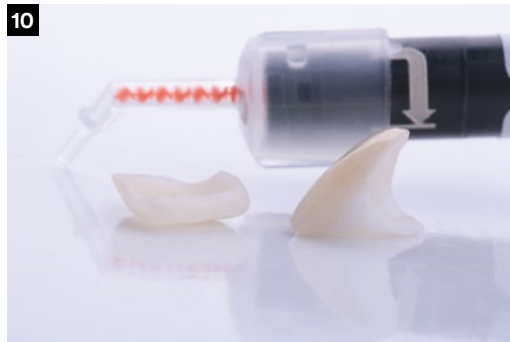

8 Total-etch of veneer preparation.

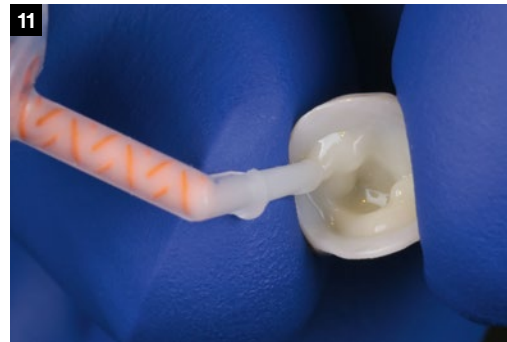

9 Application of 3M™ Scotchbond™ Universal Plus Adhesive followed by air drying.

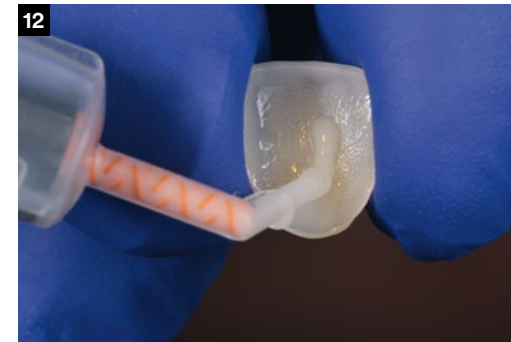**Total-etch
adhesive bonding of a glass ceramic
veneer and
self-adhesive
cementation of a
zirconia crown**



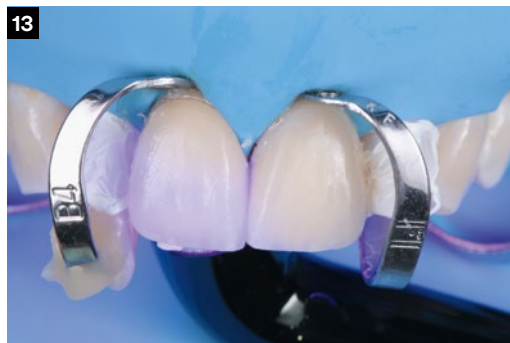10 Veneer and crown restorations ready for cementation.



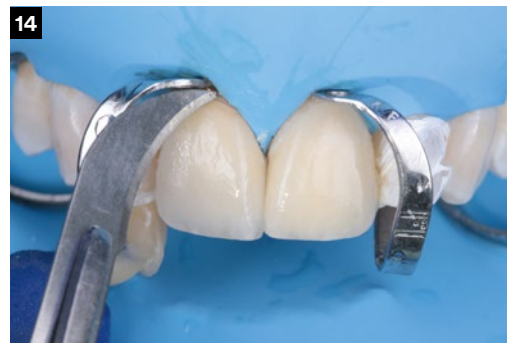11 Application of 3M™ RelyX™ Universal Resin Cement to the zirconia crown.



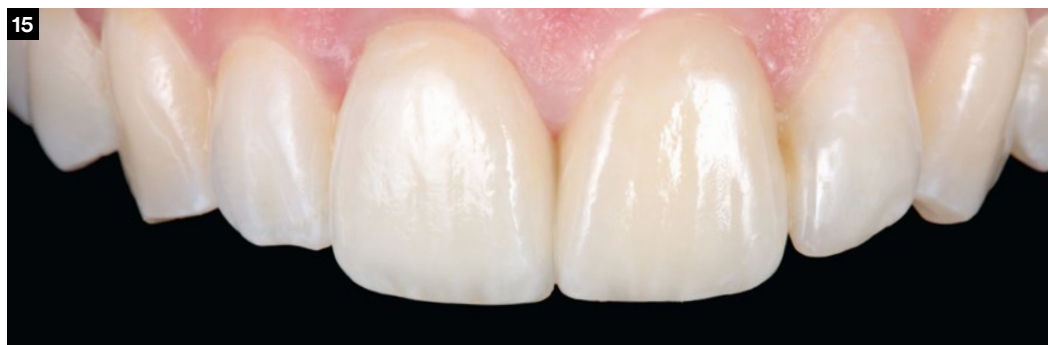12 Application of 3M™ RelyX™ Universal Resin Cement to the veneer.



13 Light-cure after clean-up.



14 Final clean-up at margins.



15 Final situation after 2 months.

Clinical Case
by Dr. Paulo Monteiro,
Portugal